

# RELIEF OF INTERNAL SNAPPING HIP SYNDROME IN A MARATHON RUNNER AFTER CHIROPRACTIC TREATMENT

Clark R. Konczak, DC,<sup>a</sup> and Rick Ames, DC<sup>b</sup>

## ABSTRACT

**Objective:** To discuss the assessment, diagnosis and chiropractic management of a patient with sacroiliac joint dysfunction (SIJ) complicated by psoas major snapping hip syndrome (*coxa saltans interna*).

**Clinical Features:** A 32-year-old male marathon runner experienced low-back and left hip pain without radiation accompanied by a “popping” in the anterior hip. He ran approximately 100 to 150 km/wk for the prior 3 years. He had stopped running for the previous 3 weeks because of worsening and consistent pain.

**Intervention and Outcome:** Treatment consisted of side posture SIJ “diversified” manipulation and myofascial release to the psoas muscle twice weekly for 2 weeks. The patient was also taught proprioceptive neuromuscular facilitation exercises of the psoas and iliotibial band muscles. He was instructed to substitute swimming instead of running on a daily basis. Reassessment at 3 weeks found the patient without pain in his hip or back and no clicking or popping in his left hip.

**Conclusion:** Clinicians should consider that runners who present with coexisting SIJ dysfunction and internal snapping hip syndrome may benefit from the combined management of both conditions. (*J Manipulative Physiol Ther* 2005;28:67.e1-67.e7)

**Key Indexing Terms:** *Running; Sports Injuries; Sacroiliac Joint; Low-Back Pain; Chiropractic; Hip*

In manual medicine, the sacroiliac joint (SIJ) is widely accepted as a potential source of low-back pain. The prevalence of sacroiliac joint dysfunction (SIJD) in the general population has been estimated to be between 13.8% and 47.9%.<sup>1-4</sup> A typical distance runner may run 130 km/wk in training and will subject his or her body to approximately 40 000 foot strikes per week. This high load is applied on a repetitive basis, increasing the potential of an injury to the SIJ.<sup>5</sup> In the running population, injuries to the SIJ are not as common as those occurring in the lower limb.<sup>6</sup> Injuries pertaining to the back, pelvis, hip, and thigh account for approximately 11% to 35% of all injuries sustained by distance runners and sprinters of varying levels of ability.<sup>1,7,8</sup> Although less common in runners, overuse injuries

of the lumbar spine and pelvis can frequently be debilitating, requiring prolonged periods of rehabilitation.<sup>9</sup>

Several papers regarding “snapping hip syndrome” refer to this syndrome as “*coxa saltans*.”<sup>4,10-14</sup> In most cases, the audible or palpable “snapping” sensation that characterizes snapping hip syndrome is painless and can be treated conservatively. Snapping hip syndrome can be attributed to a number of causes and is divided into 4 types: internal, external, posterior, and intra-articular.

Internal snapping hip syndrome (ISHS) is characterized by an audible or palpable snapping of a hypertonic iliopsoas tendon over the iliopectineal eminence as the flexed hip is extended.<sup>10,14</sup> Flexion stress of the lumbar spine is the most common cause of hypertonicity of the psoas muscle.<sup>15</sup> This can result in flexion strain on the SIJ and produce pain in the sacral area and hip.<sup>15,16</sup>

External snapping hip syndrome typically occurs when the thickened portion of the iliotibial band snaps over the greater trochanter or because of fibrosis of the gluteus maximus.<sup>14</sup> Fickel<sup>10</sup> and Schneider<sup>11</sup> both write of the possible association of snapping hip syndrome and SIJ dysfunction. Posterior snapping hip syndrome occurs when the long head of the biceps femoris moves over the ischial tuberosity.<sup>17</sup> Lastly, the iliofemoral ligaments rolling over the femoral head are responsible for the intra-articular type of snapping hip.<sup>17</sup>

Sacroiliac joint dysfunction is a term often used to describe pain in or around the region of the joint that is presumed to be caused by biomechanical disorders of the

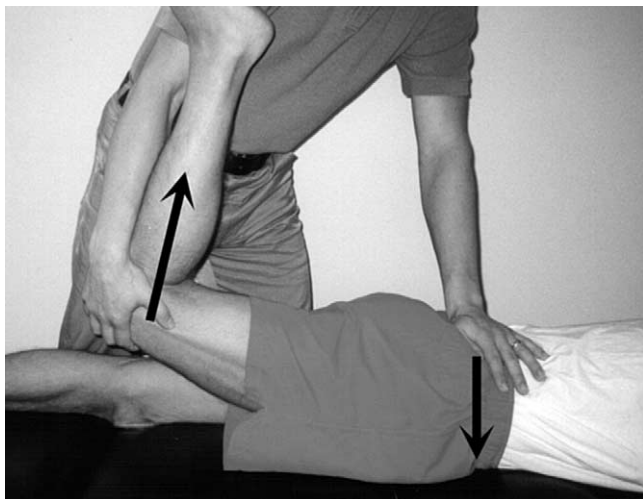
<sup>a</sup> Postgraduate student, The Chiropractic Unit, Department of Complementary Medicine, RMIT University, Bundoora, Victoria, Australia.

<sup>b</sup> Senior Lecturer, The Chiropractic Unit, Department of Complementary Medicine, RMIT University, Bundoora, Victoria, Australia.

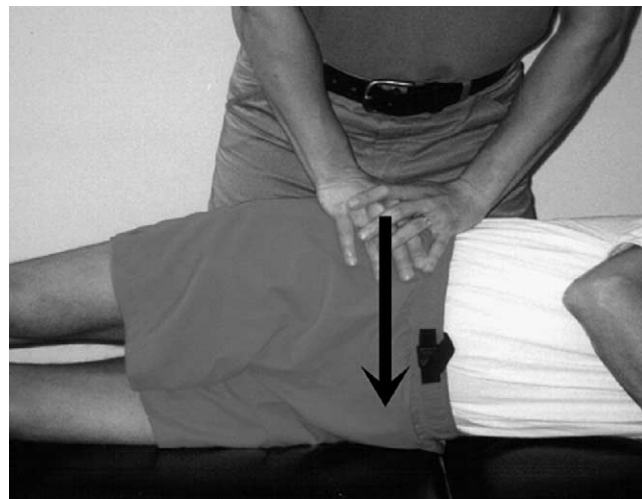
Submit requests for reprints to: Clark R. Konczak, DC, The Chiropractic Unit, Department of Complementary Medicine, RMIT University, 3936 Cumberland Road, Victoria, British Columbia, Canada V8P 3J6 (e-mail: [drkonczak@shaw.ca](mailto:drkonczak@shaw.ca)).

Paper submitted May 19, 2003 in revised form July 8, 2003.  
0161-4754/\$30.00

Copyright © 2004 by National University of Health Sciences.  
doi:10.1016/j.jmpt.2004.12.001



**Fig 1.** The Yeoman test. The prone patient's thigh is passively extended at the hip while the ipsilateral posterior superior iliac spine (PSIS) is held firmly. Reproduction of the pain of chief complaint at the ipsilateral PSIS is a positive test.



**Fig 2.** The SIJ compression test. The examiner places direct pressure to the side lying patient's pelvis in line of the SIJ. Reproduction of the pain of the chief complaint at the ipsilateral PSIS is a positive test.

joint (eg, hypomobility, malalignment, fixation, and subluxation).<sup>18</sup> This paper presents the clinical presentation, diagnosis, and chiropractic management of a case that illustrates the proposed relationship between SIJD and ISHS in a marathon runner.

## CASE REPORT

### Clinical Presentation

A 32-year-old male marathon runner had low-back and left hip pain without radiation. The pain in the low back and left hip started at the same time 6 weeks before his initial visit. He indicated the "hip pain" was on the lateral aspect of his thigh below the greater trochanter and ended approximately 10 cm above the lateral knee. The patient also indicated that his "back pain" was located 2 cm inferior to the left posterior inferior iliac spine. He attributed the complaints to no particular incident. He reported that he ran approximately 100 to 150 km/wk for approximately the last 3 years. The patient explained that his running was primarily on flat roads, but he did train by running up and down hills once per week. He denied any increase or decrease in symptoms because of variations in training. He stopped running for the previous 3 weeks because of worsening hip and back pain.

The pain in the hip and back were described as "a deep ache" and "generalized stiffness." He stated that he had the sensation of the hip being "weak" but reported no objective weakness. He frequently felt a "small pop" in the anterior left hip. Normal walking, running, and riding a bicycle aggravated both the hip and low-back pain. Resting relieved the pain, except in the morning when the pain was increased. Approximately 1 year prior, the patient had his

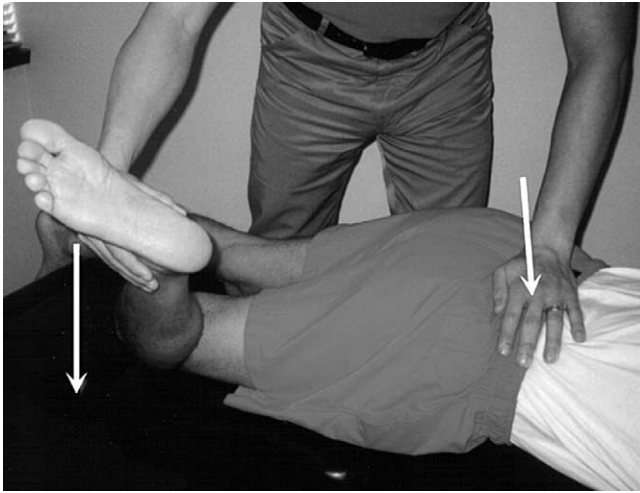
running style evaluated at a marathon clinic by a running coach. The coach found no major problems with running style but suggested that the patient buy new shoes 4 times a year to prevent injury because of the high mileage he consistently ran. The patient wore custom-made orthotic foot supports that corrected previously diagnosed bilateral hyperpronation.

He denied any other gait or health problems. He had no history of any other low-back or hip problems. For his current hip and low-back complaint, he had been receiving physiotherapy 3 times per week over the previous 3 weeks. Physiotherapy had consisted of interferential current on the lumbar paraspinal muscles for 10 minutes and supine knee to chest stretching. He had discontinued physiotherapy 5 days before his initial visit because he noted no improvement.

### Physical Examination

Examination revealed strong and equal bilateral hip strength in internal rotation, external rotation, abduction, adduction, and extension. In contrast, left hip flexion fatigued within 5 seconds compared with right hip flexion, which fatigued after 10 seconds. Lumbar spine and hip ranges of motion measured with dual inclinometry were within normal limits with the exception of left hip extension, which was decreased by 25% compared with the right. Lumbar, sacroiliac, and hip joint plays were assessed by motion palpation of the joints. Standing motion palpation showed decreased hip and SIJ play into extension on the left compared with the right.

Left Yeoman (Fig 1), SIJ compression (Fig 2), prone passive hip internal (Fig 3) and external rotation (Fig 4), and heel to buttocks tests (Fig 5) all reproduced the pain of chief complaint below the left posterior superior iliac spine.



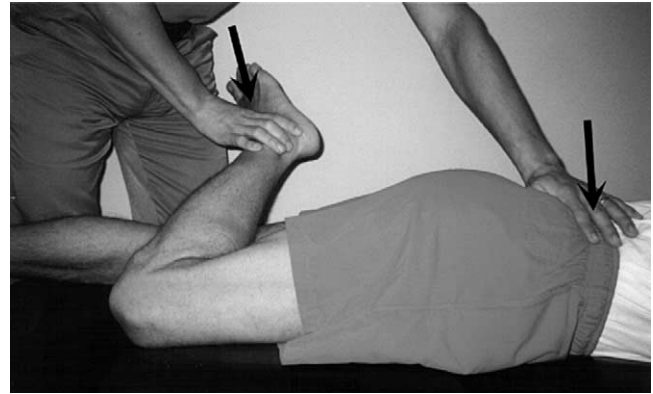
**Fig 3.** Passive hip internal rotation (Hibb test). The prone patient's thigh is passively internally rotated at the hip while the ipsilateral PSIS is held firmly. Reproduction of the pain of chief complaint at the ipsilateral PSIS is a positive test.

The same maneuvers performed on the right were unproductive. Thomas and Gaenslen tests showed slight decreased range of motion of the left hip into extension when compared with the right, suggesting hypertonicity of the left psoas muscle. Left Ober and Nobel tests showed a mildly hypertonic and tender left iliotibial band. Straight leg raise on the right was unremarkable, but on the left, passively lowering the leg to the table caused a palpable and audible click from the anterior left hip region. The patient noted the click was similar to the "pop" he frequently felt in his hip. Palpation revealed mildly hypertonic and tender lumbosacral paraspinal and erector spinae muscles on the left. On the anterior hip, the left iliopsoas tendon was tender to palpation.

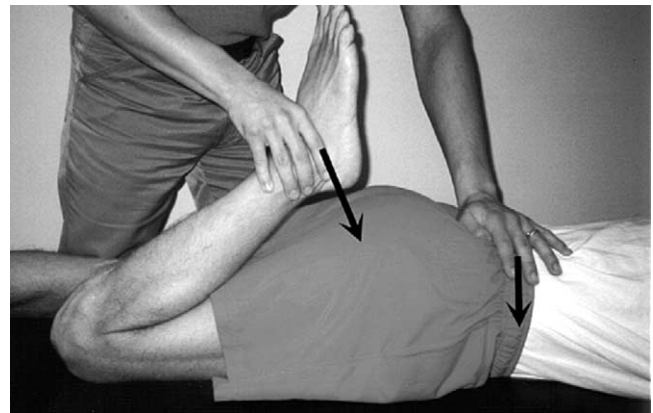
A diagnosis of left SIJD with concomitant ISHS (coxa saltans interna) was made. A mild left iliotibial band syndrome was also present.

### Treatment

Initial treatment consisted of 3 components to address both the muscular and articular aspects of the complaint. Side posture SIJ diversified manipulation<sup>19</sup> was used to enhance the motion of the hypomobile left SIJ. The patient was positioned in a comfortable side lying position with his left side up and left thigh bent less than 90° on the adjusting table. Increased isolation of the joint was achieved by minimizing counter rotation of the patient's torso and shoulders in relationship to the pelvis. An open-hand contact with the hypothenar aspect of the hand was made on the left PSIS. A high-velocity low-amplitude impulse thrust coupled with transfer of pelvic and torso weight onto the doctor's hand was applied to the left PSIS. The thrust



**Fig 4.** Passive hip external rotation. The prone patient's thigh is passively externally rotated at the hip while the ipsilateral PSIS is held firmly. Reproduction of the pain of chief complaint at the ipsilateral PSIS is a positive test.



**Fig 5.** Heel to buttock (Nachlas test). The prone patient's knee is passively flexed bringing the heel toward the buttock while the ipsilateral PSIS is held firmly. Reproduction of the pain of chief complaint at the ipsilateral PSIS is a positive test.

was along an oblique sagittal plane in an posterior to anterior and inferior to superior direction.<sup>19</sup> An audible cavitation was heard.

Myofascial release<sup>20</sup> was used to address the hypertonicity of the psoas tendon. The myofascial release used in this case involved the doctor applying moderate digital pressure to the involved tissue in a direction proximal to distal while actively moving the muscle through its range of motion in both eccentric and concentric contraction phases. This action was performed to patient tolerance 3 or 4 times per treatment session. Both manipulation and myofascial release were used during each office visit, and the patient was seen twice weekly for 2 weeks.

The patient was taught proprioceptive neuromuscular facilitation (PNF) exercises<sup>21</sup> of the psoas and iliotibial band muscles to facilitate neuromuscular reeducation. The PNF

exercises consisted of 3 sets of 5 repetitions or cycles. The patient was instructed to do the exercises 5 times a day with approximately 1 to 2 hours between sets. He was also instructed to incorporate breathing techniques to enhance relaxation. The patient was instructed in 2 types of PNF exercises. "Hold-relax" PNF exercises involved an isometric contraction of the muscle and "contract-relax" used isotonic resistance.<sup>21</sup> He was instructed to substitute a half hour of daily swimming instead of running.

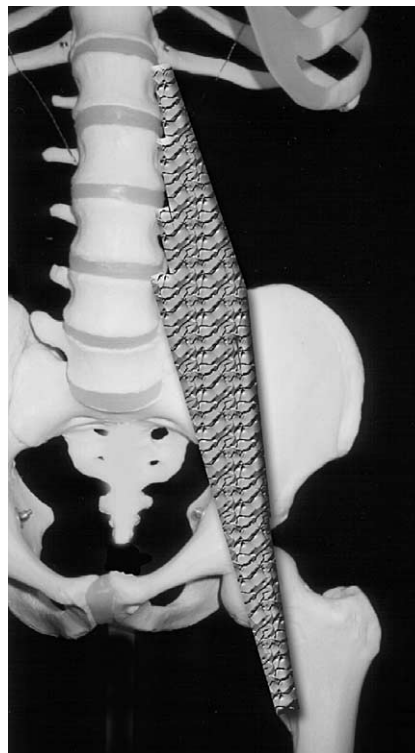
The patient noted immediate improvement in all his symptoms the day after the first treatment. When asked to rate his improvement from 0% to 100%, he stated that he was "25% improved." One week later, the patient had noted continued improvement and rated his improvement as "75% improved." Because of the decrease in his symptoms, the patient decided to run 5-km distances every day and did so without any increase in symptoms. Two weeks after the onset of treatment, he was significantly improved and was running 10 km at a time without symptoms. At this time, the patient stated that he "feels great, 95%." The patient in this case also commented that he was satisfied that he could return to running and training in the period of less than 3 weeks. This is consistent with Engsborg et al,<sup>22</sup> who state that the majority of runners are pleased that they can maintain regular training during chiropractic treatment.

At this time of treatment, frequency was decreased to 1 time per week, and PNF exercises for the lower extremity were taught to the patient with the goal of preventing future injury. The PNF exercises included the addition of the gastrocnemius, soleus, hamstrings, quadriceps, gluteals, and hip adductors.<sup>21</sup>

Reassessment at 3 weeks found the patient without pain in his hip or back, no clicking or popping in his left hip. The patient described the condition as "100%" improved. Bilateral hip flexor strength was equal and strong, and both the right and left took longer than 10 seconds to fatigue. Lumbar, sacroiliac, and hip joint plays had no restrictions. Left Yeoman, SIJ compression, prone passive hip internal and external rotation, and heel to buttocks no longer provoked pain. Thomas and Gaenslen tests showed minimal and equal bilateral psoas tightness and no pain. Ober and Nobel tests showed normal tone and absence of tenderness in the left iliotibial band. Palpation revealed normal tone of the lumbosacral paraspinal, erector spinae muscles, and iliopsoas tendon which were not tender to palpation. The patient was released from treatment. Two weeks after the end of treatment, he ran a 42-km marathon and then another 42-km marathon 6 weeks after the end of treatment without hip or back symptoms. A 6-month follow-up reexamination found the patient still asymptomatic.

### Differential Diagnosis

The hip and the pelvis are commonly injured in athletes. A variety of sports injuries in the soft tissues or bones may



**Fig 6.** Computer illustration of the psoas major muscle. The muscle attaches by slender fasciculi cranially to the medioventral surface of the T12 to L4 vertebral bodies and disk and caudally to the ventrocaudal borders of the lumbar transverse processes. The psoas major passes anterior to the SIJ caudally and anterior to the upper part of the hip joint. It inserts on the lesser trochanter of the femur together with the iliacus muscle to form the iliopsoas muscle. (Illustration created by author).

involve the pelvis and the hip. The most common sports-related injuries in the hip, pelvis, and thigh areas are muscle-tendon conditions involving the adductors, hamstrings, abdominals, iliopsoas (ISHS), rectus femoris, and the iliotibial band (external snapping hip syndrome).<sup>23-25</sup>

Sacroiliac joint syndrome and posterior joint syndromes are the most common referred pain syndromes.<sup>26,27</sup> Herniated nucleus pulposus and lateral spinal stenosis are the most common nerve root compression lesions.<sup>26</sup> Referred pain syndromes occur nearly twice as often and frequently mimic the clinical presentation of nerve root compression syndromes.<sup>26</sup> Combined lesions occurred in 33.5% of cases.<sup>26</sup> It is suggested that sacroiliac syndromes can coexist with lumbosacral anomalies.<sup>28</sup>

Sacroiliac joint dysfunction is diagnosed by physical examination. No laboratory or radiographic examinations for SIJD exist.<sup>29,30</sup> Our criteria for the diagnosis of SIJD in this case included positive SIJ pain provocation tests and absence of radiculopathy or other anatomic abnormality. Provocation tests were deemed positive if familiar, similar, concordant pain occurred while the SIJ in question was tested. Evidence of abnormal SIJ motion was identified and

considered in this case but given less priority in arriving at the diagnosis. This was done because despite little data to support the use of symmetry or movement tests in the diagnosis of SIJD, there is some evidence that supports the use of pain provocation tests and the patient's report of pain.<sup>2,8,29,31,32</sup>

Regarding the treatment of SIJD, the medical literature advocates the use of bed rest, heat, cryotherapy, nonsteroidal anti-inflammatory drugs, and muscle relaxants. In recalcitrant cases, fluoroscopically guided injection of the SIJ with a corticosteroid and a local anesthetic or sodium hyaluronate (a hyaluronic acid derivative) can be effective.<sup>33</sup> Chiropractic treatment of SIJD often includes manipulation to the involved SIJ, cryotherapy, and stretches and/or exercises to the adjacent musculature.<sup>10,34,35</sup>

The presence of ISHS was identified by an audible and palpable snapping of a hypertonic iliopsoas tendon over the iliopectineal eminence (Fig 6) as the patient's flexed hip was extended.<sup>10,14</sup> Choi et al<sup>12</sup> and Pelsser et al<sup>36</sup> looked at ISHS with dynamic ultrasonography of the iliopsoas tendon during hip motion in patients with snapping hip syndrome. Distinct abnormal motion of the tendon corresponding temporally to the painful palpable and audible sensation was shown in both studies.<sup>12,36</sup> Iliotibial band syndrome was identified by pain in the left lateral hip, and the pain was reproduced by palpation and orthopedic tests that stressed the iliotibial band. Additional orthopedic testing showed contracture of the iliotibial band. These findings were in absence of other hip or knee abnormalities.

## DISCUSSION

Meckel<sup>37</sup> first described motion in the SIJ in 1816. Since then, many investigations have been made regarding the quantity and quality of motion within the SIJ.

The SIJ is a strong joint with limited mobility. It mechanically serves as a force transducer and a shock absorber. The gluteus maximus and piriformis muscles blend with the SIJ ligaments. The psoas muscle does not directly interact with the SIJ but does superimpose itself over the anterior joint and contributes to SIJ flexion, as well as the self-bracing mechanism of the pelvis.<sup>38,39</sup> The SIJ has a complex role as part of 3 closed kinematic chains involving the lumbar spine, sacrum, pelvic girdle, and lower extremities. When problems exist in 1 of the kinetic chains, this will cause dysfunction around and within the other 2 joint systems.<sup>38,39</sup>

The SIJ has been questioned as a source of low-back pain, because it is suggested that well-recognized pain-sensitive structures, such as the posterior facet joints and nerve roots, may refer pain to the SIJ region. The anatomy and location of the SIJ complicate the situation, because examination procedures presumed to test the joint may actually test other structures in the region. The English

medical literature describes dozens of test procedures for the examination of the SIJ. Many of these tests have not shown reasonable levels of validity or reliability.<sup>1,2,8,18,29-31,40-42</sup> Currently, the most reliable method shown to establish the diagnosis of SIJD is fluoroscopic-guided intra-articular injection of a local anesthetic preceded by a sacroiliac arthrogram.<sup>17,43,44</sup>

Many studies do not support the use of a single provocative SIJ maneuver to confirm a diagnosis of SIJD.<sup>2,29,30,41,42</sup> A single positive maneuver can, at best, enter SIJD into the differential diagnosis. However, studies suggest that a multitest regimen of 3 to 5 SIJ pain provocation tests may be a reliable method to evaluate SIJD.<sup>2,8,29,31,32</sup>

With regards to the lumbar spine, pelvis, and hips, the relationship between disturbances to the normal kinematic pattern of these segments during running and increased incidence of injury has been reported.<sup>45</sup> Lewit<sup>46</sup> suggests that both soft tissue and osseous factors are present in articular dysfunction and that either factor may predominate in any particular case. Anterior pelvic tilt, thought to be associated with tightness of the psoas major muscle,<sup>45</sup> or increased lumbar lordosis caused by tight erector spinae<sup>47</sup> are examples of other abnormalities.

Studies have assessed and recognized the coordinated movements of the knee, ankle, and subtalar joints during running.<sup>48</sup> In comparison, research on the integrated biomechanical function of the lumbar-pelvis-hip complex during running is less common.<sup>49</sup> The mechanics of the joint complex has been studied using infrared markers, pressure plates, and electromyography.<sup>6,48,50-53</sup> The lumbar-pelvis-hip complex is highly coordinated during running.<sup>3,17,43</sup> Awareness of the coordination and interaction of the osseous and muscular factors may facilitate the rehabilitation of running injuries to the pelvis and hip.

## CONCLUSION

This paper discusses the assessment, diagnosis, and treatment of the proposed relationship between ISHS and SIJD in a marathon runner. Although SIJD is recognized as a cause of low-back pain in runners, its precise role is still under debate. One potential reason that SIJD is still controversial may be because of coexisting conditions such as ISHS complicating the clinical picture. Clinicians should consider that runners who present with coexisting SIJD and ISHS may benefit from the combined management of both conditions.

## REFERENCES

1. Toussaint R, Gawlik CS, Rehder U, R  ther W. Sacroiliac dysfunction in construction workers. *J Manipulative Physiol Ther* 1999;22:134-8.

2. Gemmell HA, Jacobson BH. Incidence of sacroiliac joint dysfunction and low back pain in fit college students. *J Manipulative Physiol Ther* 1990;13:63-7.
3. McCombe PF, Fairbank JCT, Cockersole BC, Pynsent PB. 1989 Volvo Award in clinical sciences: reproducibility of physical signs in low-back pain. *Spine* 1989;14:908-18.
4. Allen WC, Cope R. Coxa saltans: the snapping hip revisited. *J Am Acad Orthop Surg* 1995;3:303-8.
5. Cavanagh PR, LaFortune MA. Ground reaction forces in distance running. *J Biomech* 1980;13:397-406.
6. Schache A, Blanch P, Rath D, Wrigley T, Bennell K. Three-dimensional angular kinematics of the lumbar spine and pelvis during running. *Hum Mov Sci* 2002;21:273-93.
7. Lysholm J, Wiklander J. Injuries in runners. *Am J Sports Med* 1987;15:168-71.
8. Kokmeyer DJ, van der Wurff P, Aufdemkampe G, Fickenscher TC. The reliability of multitest regimens with sacroiliac pain provocation tests. *J Manipulative Physiol Ther* 2002; 25:42-8.
9. Bennell KL, Crossley K. Musculoskeletal injuries in track and field: incidence, distribution and risk factors. *Aust J Sci Med Sport* 1996;28:69-75.
10. Fickel TE. 'Snapping hip' and sacroiliac sprain: example of a cause-effect relationship. *J Manipulative Physiol Ther* 1989;12:390-2.
11. Schneider MJ. 'Snapping hip' and sacroiliac sprain: example of a cause-effect relationship (letter). *J Manipulative Physiol Ther* 1990;13:114-7.
12. Choi YS, Lee SM, Song BY, Paik SH, Yoon YK. Dynamic sonography of external snapping hip syndrome. *J Ultrasound Med* 2002;21:753-8.
13. Brignall CG, Brown RM, Stainsby GD. Fibrosis of the gluteus maximus as a cause of snapping hip. A case report. *J Bone Joint Surg Am* 1993;75:909-10.
14. Gruen GS, Scioscia TN, Lowenstein JE. The surgical treatment of internal snapping hip. *Am J Sports Med* 2002; 30:607-13.
15. Kappler RE. Role of psoas mechanism in low back complaints. *J Am Osteopath Assoc* 1973;72:794-801.
16. Bachrach R, Micelotta J, Winuk C. The relationship of low back pain to psoas insufficiency. *J Orthop Med* 1991;13:34-40.
17. De Paulis F, Cacchio A, Michelini O, Maniani A, Saggini R. Sports injuries to the pelvis and hip: diagnostic imaging. *Eur J Rad* 1998;27:S49-59.
18. Dreyfuss P, Dreyer S, Griffin J, Hoffman J, Walsh N. Positive sacroiliac screening tests in asymptomatic adults. *Spine* 1994;19:1138-43.
19. Bergmann T, Peterson D, Lawrence D. Chiropractic technique. New York, NY: Churchill Livingstone Inc.; 1993. p. 499-500.
20. Leahy M, Mock L. Myofascial release technique and mechanical compromise of peripheral nerves of the upper extremity. *Chiropr Tech* 1992;6:139-50.
21. Liebensohn C. Rehabilitation of the spine: a practitioner's manual. Baltimore, MD: Williams and Wilkins; 1996. p. 253-92.
22. Engsborg JR, Grimston SK, Shaw L. Muscular rehabilitation prescribed in coordination with prior chiropractic therapy as a treatment for sacroiliac subluxation. *Chiro Sports Med* 1990;4:2-8.
23. Major NM, Helms CA. Pelvic stress injuries: the relationship between osteitis pubis (symphysis pubis stress injury) and sacroiliac abnormalities in athletes. *Skeletal Radiol* 1997;26: 711-7.
24. Johnston CA, Wiley JP, Lindsay DM, Wiseman DA. Iliopsoas bursitis and tendinitis. A review. *Sports Med* 1998;25:271-83.
25. Rothbart BA, Estabrook L. Excessive pronation: a major biomechanical determinant in the development of chondromalacia and pelvic lists. *J Manipulative Physiol Ther* 1988; 11:373-9.
26. Bernard TN, Kirkaldy-Willis WH. Recognizing specific characteristics of nonspecific low back pain. *Clin Orthop Relat Res* 1997;Apr:266-80.
27. Newton W, Curtis P, Witt P, Hobler K. Prevalence of subtypes of low back pain in a defined population. *J Fam Pract* 1997;45:331-5.
28. Bressler HB, Deltoff MN. Sacroiliac syndrome associated with lumbosacral anomalies: a case report. *J Manipulative Physiol Ther* 1984;7:171-3.
29. Gillet H. Clinical measurement of sacroiliac mobility. *Ann Swiss Chiropr Assoc* 1976;6:59-70.
30. Laslett M, Williams M. The reliability of selected pain provocation tests for sacroiliac joint pathology. *Spine* 1994;19:1243-9.
31. Meijne W, van Neerbos K, Aufdemkampe G, van der Wurff P. Intraexaminer and interexaminer reliability of the Gillet test. *J Manipulative Physiol Ther* 1999;22:4-9.
32. Freburger J, Riddle K. Using published evidence to guide the examination of the sacroiliac joint region. *Phys Ther* 2001;81: 1135-43.
33. Sasso RC, Ahmad RI, Butler JE, Reimers DL. Sacroiliac joint dysfunction: a long-term follow-up study. *Orthopedics* 2001; 24:457.
34. Lindberg L. Sprain and subluxation of the right sacroiliac joint with associated muscle spasm in the right gluteal area: short report. *Chiropr Tech* 1997;9:137-9.
35. Mooney V, Pozos R, Vleeming A, Gulick J, Swenski D. Exercise treatment for sacroiliac pain. *Orthopedics* 2001;24: 29-32.
36. Pelsser V, Cardinal E, Hobden R, Aubdin B, Lafortune M. Extraarticular snapping hip: sonographic findings. *Am J Roentgenol* 2001;176:67-73.
37. Meckel JF. *Handbuch der menschlichen anatomie*. Berlin, Germany: Halle; 1816.
38. Hendlner N, Kozikowski J, Morrison C. Diagnosis and management of sacroiliac joint disease. *J Neuromusculoskeletal Syst* 1995;3:169-74.
39. Harrison DE, Harrison DD, Troyanovich SJ. The sacroiliac joint: a review of anatomy and biomechanics with clinical implications. *J Manipulative Physiol Ther* 1997; 20:607-17.
40. Hestaek L, Leboeuf-Yde C. Are chiropractic tests for the lumbo-sacral spine reliable and valid? A systemic review. *J Manipulative Physiol Ther* 2000;23:258-75.
41. Tabar J. Treatment of sacroiliac joint: a review of procedures. *Chiropr Tech* 1997;9:185-92.
42. Potter NA, Rothstein JM. Intertester reliability for selected tests of the sacroiliac joint. *Phys Ther* 1985;65:1671-5.
43. Herzog W, Nigg BM, Robinson RO, Read LJ. Quantifying the effects of spinal manipulations on gait, using patients with low back pain: a pilot study. *J Manipulative Physiol Ther* 1987; 10:295-9.
44. van der Wurff P, Meyne W, Hagmeijer R. Clinical tests of the sacroiliac joint. A systemic and methodological review. Part 2: validity. *Man Ther* 2000;5:89-96.
45. Bogduk N, Percy M, Hadfield G. Anatomy and biomechanics of psoas major. *Clin Biomech* 1992;7:109-15.
46. Lewit K. Management of muscular pain associated with articular dysfunction. In: Friction JR, Awad E, editors. *Advances in pain research and therapy*. New York, NY: Raven Press; 1990. p. 315-23.

47. Bach D, Green K, Jensen G, Savinar E. A comparison of muscular tightness in runner and nonrunners and the relation of muscular tightness to low back pain in runners. *J Orthop Sports Phys Ther* 1985;6:315-23.
48. Nawoczenski DA, Saltzman CL, Cook TM. The effect of foot structure on the three-dimensional kinematic coupling behavior of the leg and rear foot. *Phys Ther* 1998;78:404-16.
49. Fortin JD. Sacroiliac joint dysfunction: a new perspective. *J Back Musculoskelet Rehabil* 1993;3:31-43.
50. Stuesson B, Selvik G, Uden A. Movements of the sacroiliac joints. *Spine* 1989;14:162-5.
51. Jacob H, Kissling R. The mobility of the sacroiliac joints in healthy volunteers between 20 and 50 years of age. *Clin Biomech* 1995;10:352-61.
52. Wang M, Bryant J, Dumas G. A new in vitro measurement technique for small three-dimensional joint motion and its application to the sacroiliac joint. *Med Eng Phys* 1996; 18:495-501.
53. Levin U, Stenstrom C. Force and time recording for validating the sacroiliac joint distraction test. *Clin Biomech* 2003;18: 821-6.